

Four hand injuries not to miss: avoiding pitfalls in the emergency department

Philip Yoong^a, Catherine A. Johnson^a, Edward Yoong^c and Adrian Chojnowski^b

The clinical and radiological findings in some hand injuries can be subtle and easily misinterpreted, leading to irreversible changes and profound functional loss. The importance of early and accurate diagnosis is clear. This study looks at four such injuries, with reference to pertinent anatomy, typical mechanisms of injury, examination and radiological findings, with emphasis on avoiding pitfalls in the emergency department. *European Journal of Emergency Medicine* 00:000–000 © 2011 Wolters Kluwer Health | Lippincott Williams & Wilkins.

European Journal of Emergency Medicine 2011, 00:000–000

Keywords: emergency medicine, hand injuries, upper extremity, wounds and injuries

^aNorwich Radiology Academy, ^bDepartment of Trauma and Orthopaedics, Norfolk and Norwich University Hospital, Norwich, Norfolk and ^cSchool of Medicine, University of Manchester, Manchester, UK

Correspondence to Dr Philip Yoong, MBBS, Norwich Radiology Academy, Cotman Centre, Colney Lane, Norwich NR4 7UB, UK
Tel: +44 1603 286140; fax: +44 1603 286077;
e-mail: philip.yoong@nnuh.nhs.uk

Received 7 September 2010 Accepted 17 November 2010

Introduction

Upper limb injuries are commonly seen in the emergency department [1]: fractures of the upper limb comprise approximately half of all fractures seen [2]. Much emphasis is made on the distal radius, elbow and shoulder: fractures here are frequently seen and usually well managed. In contrast, we describe four injuries of the hand that may be outside the core knowledge base of junior clinicians. As a consequence, these injuries are sometimes missed, misdiagnosed or underestimated, with significant impact on hand function [3]. The resulting time delay to correct diagnosis leads to irreversible changes, which cannot be corrected even with optimum orthopaedic care. This has medico-legal implications for the emergency physician [4]. Typical mechanisms of injury, relevant anatomy, clinical and radiological findings and treatment are discussed, along with the consequences of delayed or inadequate treatment.

Ulnar collateral ligament injury

The thumb has a critical role in pinching and grasping, estimated to account for 50% of hand function [5]. The thumb metacarpophalangeal (MCP) joint is stabilized by two collateral ligaments, which limit lateral motion; the radial and ulnar collateral ligaments. Although both are important in MCP joint stability [6], the latter is much more frequently injured [7]. The ulnar collateral ligament (UCL) runs from the head of the thumb metacarpal to the inner aspect of the proximal phalanx base [8], acting to restrict lateral motion at the MCP joint. There are two portions to the collateral ligament: the proper and accessory ligaments [9].

Injury to the UCL may result in loss of thumb pinch grip, power and early osteoarthritis if untreated [10]. Early

and accurate diagnosis is therefore essential. A sudden forced abduction of the thumb is typical [11], most commonly in the context of trauma or contact sports. Skiers are especially prone to this injury when falling while holding a ski pole with the injured hand, hence the term 'Skier's thumb' [12]. In contrast, repetitive minor injury to the UCL results in a chronic laxity known as 'Gamekeeper's thumb', eponymously described in Scottish gamekeepers who would break the necks of rabbits between the thumb and index finger [13]. The term 'Acute gamekeeper's thumb' is therefore a misnomer.

A diagnosis may be obtained with a careful history and examination. There is usually a history of a sporting injury, resulting in pain at the base of the thumb. On examination, reduced motion at the thumb MCP joint, with maximal tenderness over the ulnar aspect is suggestive. However, a stress examination of the UCL is critical when there is no associated avulsion fracture (see below). Lateral (valgus) stress is applied to both injured and uninjured thumbs. Opinions vary, but there is evidence that angulation of over 35 or 15° more than on the uninjured side is indicative of a complete rupture [14]. However, in the clinical environment, precise assessment of the degree of laxity can be difficult due to pain. Local anaesthesia can therefore be used before manipulation [15]. As the lack of a defined end-point also suggests a complete rupture [16], this may be a more useful discriminator. When stress testing, the MCP joint should be stabilized proximal to the joint to prevent rotation and the joint should be stressed in both flexion and extension. Significant laxity in flexion indicates a rupture of the proper collateral ligament, which is taut in flexion; laxity in extension indicates rupture to the accessory collateral ligament [17].

Supplemental digital content is available for this article. Direct URL citations appear in the printed text and are provided in the HTML and PDF versions of this article on the journal's website (www.euro-emergencymed.com).

It is important to try and distinguish between a complete and incomplete rupture, as their treatment is different. An incomplete rupture or sprain can be suitably treated with immobilization and subsequent hand therapy; a complete rupture requires surgery. Rupture usually occurs distally, at the insertion into the proximal phalanx [18]. A complete rupture involves both the accessory and proper collateral ligaments, and is often associated with a 'Stener lesion', in which the distal end of the UCL is displaced proximally superficial to the adductor aponeurosis [19], preventing anatomical healing (Fig. 1).

Radiographs are not diagnostic, but may assist in several ways. Ideally, these should be obtained before a stress test, to prevent further theoretical displacement of an avulsion fracture [20]. Concomitant injuries to nearby bones may be excluded, including the scaphoid and a Bennett's fracture. UCL injury is associated with a typical avulsion fracture from the ulnar base of the thumb proximal phalanx [21,22], but this is only present in 50% of injuries (Fig. 1). If this fracture is displaced proximally, it may indicate a 'Bony Stener' lesion that is indicative of a complete rupture [23,24], requiring surgery. In the absence of a fracture, subtle radial deviation at the thumb MCP joint is suggestive [6]. A true lateral radiograph of the MCP joint should be inspected for palmar subluxation as it indicates an unstable injury involving a dorsal capsular and collateral ligament tear, necessitating surgery [25]. Stress radiographs and MRI scanning are rarely of use in assessment: clinical history, examination and plain radiographs are usually sufficient [26], although ultrasound may have a role in equivocal cases [27].

UCL injury usually has characteristic history and examination findings. Untreated injuries may result in significant compromise of hand function. In the emergency

department, we would therefore recommend that all suspected UCL injuries are immobilized in a thumb spica, keeping the interphalangeal joint free to reduce stiffness, and promptly referred to a hand surgeon for further assessment. Although less common, radial collateral ligament (RCL) injuries can also be very disabling and the clinician should palpate and stress this area of the thumb MCP joint as well [28].

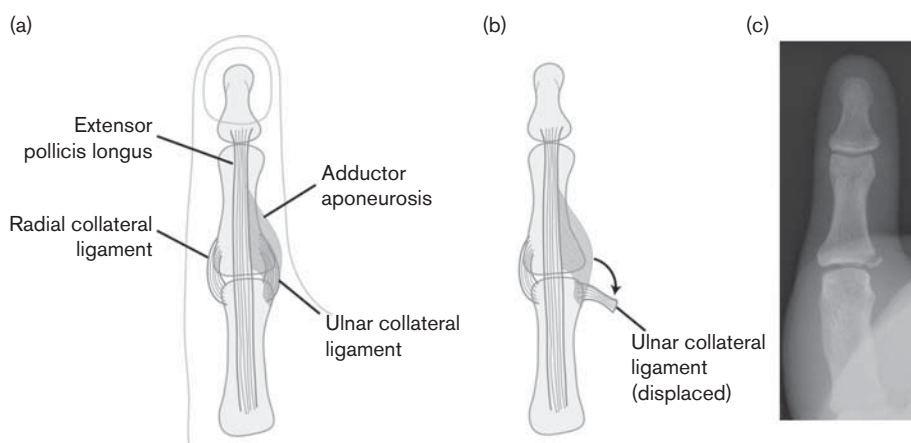
Base of metacarpal: Bennett's fracture

Bennett's fracture is a two part, oblique intra-articular fracture subluxation of the base of the thumb metacarpal [29]. It is typically sustained from a fall producing an axial load on a flexed thumb metacarpal [30]. The most common first metacarpal fracture [31], its ability to negatively impact on hand function is often underestimated.

A smaller volar-ulnar fragment retains ligamentous attachment to the trapezium at the first carpometacarpal (CMC) joint, whereas the rest of the metacarpal subluxes proximally and radially, primarily due to the attachment of the abductor pollicis longus tendon (Fig. 2). This feature confers an inherent instability to this fracture [32], which is prone to displace without some form of surgical fixation (Fig. 2). Failure to obtain a stable and congruent CMC joint increases the risk of early osteoarthritis, resulting in disabling pain and stiffness [33]. Even a 1 mm malunion can result in residual symptoms [34]. It is therefore accepted that this fracture is best treated with surgery [32,35].

Typically, a patient presents with pain and swelling to the thumb base. It is important to closely examine the available views for concomitant injuries, particularly to the UCL and the scaphoid. A triangular ulnar fragment

Fig. 1



(a) Simplified diagram of the normal anatomy of the thumb metacarpophalangeal joint. (b) Normally lying under the adductor aponeurosis; if torn the ulnar collateral ligament (UCL) often displaces, lying superficial to it; in this position anatomical healing cannot occur. (c) This is the Stener lesion. A lateral avulsion fracture from the base of the proximal phalanx is indicative of a UCL injury.

Fig. 2

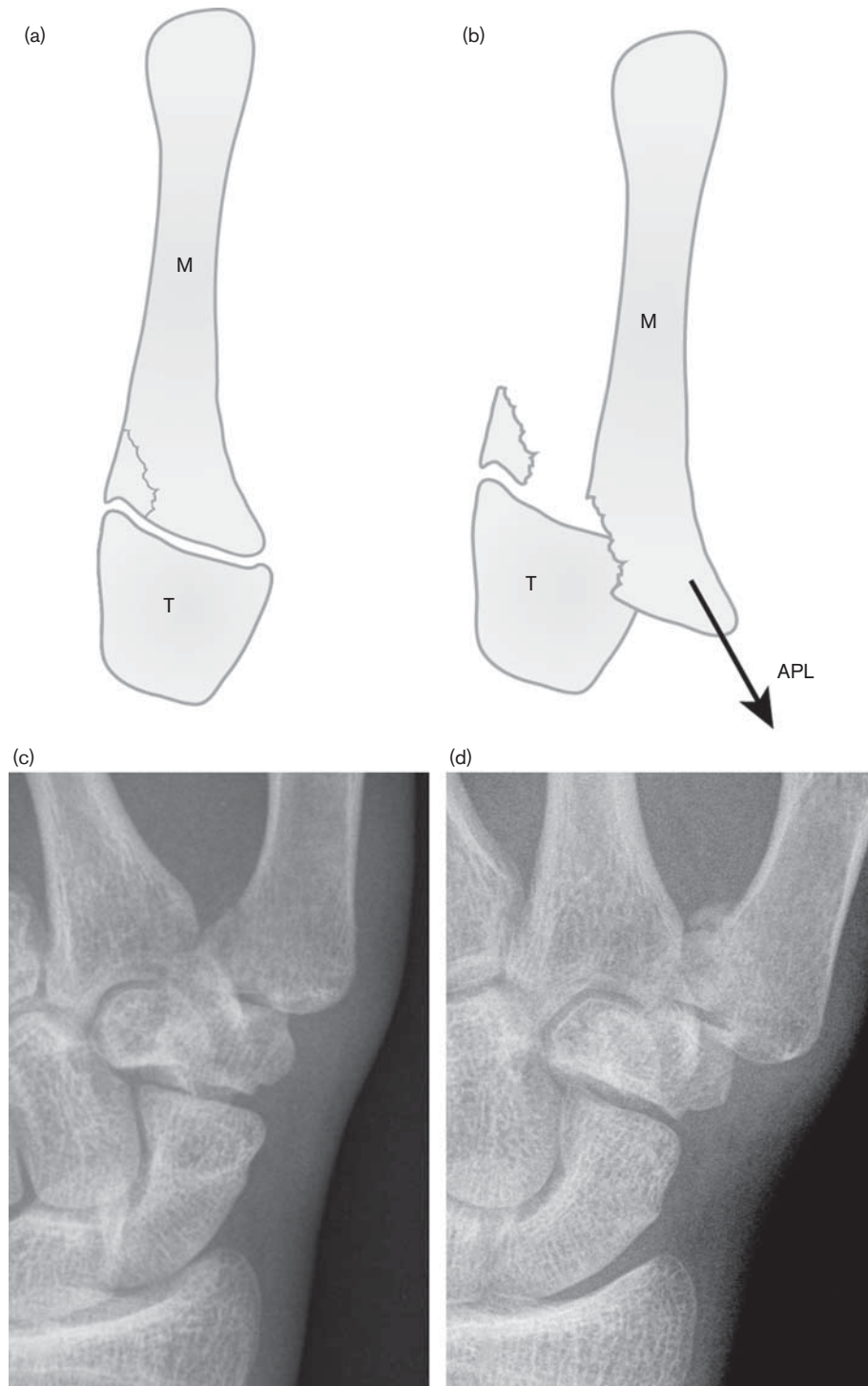


Diagram showing the inherent instability of Bennett's fracture. A volar–ulnar fragment of bone remains attached to the trapezium (T), whereas the remainder of the metacarpal (M) subluxes dorsally due to the pull of the abductor pollicis longus (APL) tendon (a and b). An initially undisplaced fracture (c) displaces after 6 weeks of nonoperative treatment resulting in a painful, stiff joint (d).

of bone at the first CMC, with an associated proximal displacement of the remainder of the metacarpal, is seen in a Bennett's fracture. The size of the volar fragment

and extent of proximal displacement varies greatly: an impacted fracture with little displacement may be missed. An unexpected sharp kink of angulated cortex is suggestive

(Supplementary Fig. 1, Supplementary digital content 1 <https://docs.google.com/leaf?id=0B6sz8zJWgrDVOTZjMmFjZDArODNhNS00Njg3LWEyMDkrODQ5MDAwNmQxZjcw&hl=en&authkey=CJv1zIAJ>), although appearances may be subtle.

In the emergency department, the diagnosis of Bennett's fracture should routinely result in a prompt referral to an orthopaedic surgeon, as all cases benefit from early surgical fixation. Delay in diagnosis and treatment predisposes towards long-term impairment of thumb function.

Volar plate avulsion fracture

The proximal interphalangeal (PIP) joint is a hinge joint, which is capable of the largest range of motion in the hand (0–110°) [36]. It is stabilized by several important structures, including the volar (palmar) plate. This is a strong fibrous structure connecting the palmar aspect of the middle and proximal phalanges (Fig. 3), which stabilizes the PIP joint by limiting hyperextension [37]. Volar plate injury has typical history, examination and radiological findings. The failure to recognize and promptly treat these injuries can result in disabling pain, stiffness and deformity through early osteoarthritis [38].

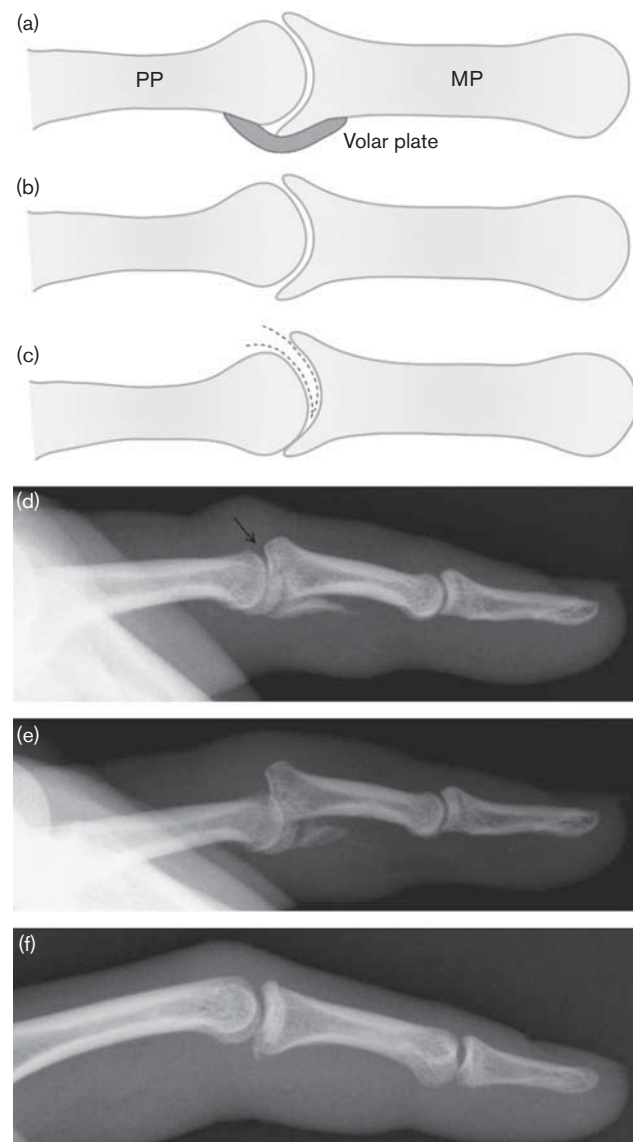
A characteristic history is of forced hyperextension resulting in pain over the palmar aspect of PIP joint, bruising, swelling and a reduced range of movement. There may be a history of deformity and attempted reduction of a presumed dislocation before arrival in the emergency department. It is a common injury in athletes, particularly ball sports [39].

Quality plain radiographs are the only modality for both initial assessment and subsequent follow-up of this injury. A true lateral of the injured digit is essential [38]; volar plate injury is most apparent in the sagittal plane.

Dorsal or palmar dislocation should be reduced and a repeat X-ray is obtained. A fracture of the articular surface needs to be carefully evaluated as it may lead to instability with subtle subluxation of the joint. If present, this will cause significant loss of joint mobility and predispose towards early arthrosis. A dorsal PIP joint dislocation should prompt the emergency physician to carefully assess for signs of a volar plate injury.

The lateral view is the key view to inspect. The radiographic appearances are very variable. An avulsion fracture at the distal attachment at the middle phalanx base is characteristic [39] but not diagnostic. The absence of a fracture does not exclude this injury; but correlates with a good prognosis. A volar plate injury with only a small fracture and no joint subluxation can be treated conservatively, with early mobilization and physiotherapy [40]. The size of this fracture may range from a tiny flake of bone (Fig. 3) to a large displaced fracture involving over half the articular surface; with increasing fracture size the PIP joint becomes more unstable. If more than 40% of the articular

Fig. 3



Illustrative diagram of the normal volar plate (a). In (b), the joint is congruent; in (c), joint subluxation results in a dorsal crescentic gap indicating instability, the 'V sign', shown on a plain radiograph (d). After several weeks without treatment, further subluxation and malunion has occurred (e). A subtle volar plate avulsion fracture without subluxation is also shown (f).

surface is involved in a fracture it is best treated with surgical stabilization [39] as the joint is now unstable. This is because a fracture of this size frequently involves the attachment of the stabilizing collateral ligaments [41]; consequently, the joint will lie displaced despite any reduction attempts.

In our experience, the diagnostic challenge in the emergency department is subtle subluxation of the PIP joint. If untreated frequently leads to early osteoarthritis, stiffness and loss of function. A practical method of showing subluxation is through the 'V' sign on a true

lateral radiograph [42]. This describes a crescent shaped gap at the dorsal aspect of an incongruous PIP joint (Fig. 3). We make two recommendations: that a true lateral film of an injured PIP joint must be obtained, and that the presence of subluxation in the form of a 'V' sign on a true lateral merits a specialist referral.

Flexor digitorum profundus avulsion

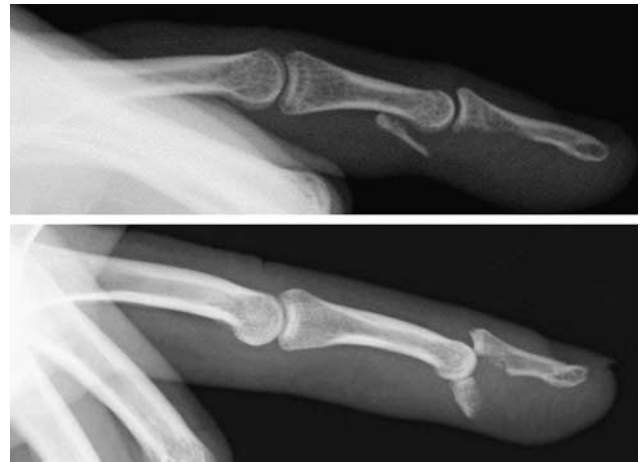The tendon responsible for flexion at the distal interphalangeal (DIP) joint of the finger is the flexor digitorum profundus (FDP) tendon. Originating in the forearm, it travels through the carpal tunnel and along the digit through a series of pulleys, inserting into the palmar base of the distal phalanx [43]. Avulsion of the FDP at its insertion is a commonly misdiagnosed injury: there are often normal radiographs and a finger that is able to actively flex at the PIP and MCP joints. Prompt diagnosis and treatment is important: only reattachment of the FDP can restore active flexion at the DIP joint and early surgery is much more successful [44].

Again, there is usually a history of injury during sporting activity: the colloquial term 'Rugby jersey finger' is testament to this [45]. The ring finger is most susceptible to this injury [46,47]. Typically, a sportsman is grasping the jersey of an opposing player who subsequently pulls away. This results in a sudden extension of an actively contracted (i.e. flexed DIP joint) profundus tendon, and avulses the FDP from its insertion [45,48]. This history is important and will help clinch a diagnosis.

On examination, there is often a swollen, bruised distal digit. It is critical to examine FDP function by blocking the PIP joint in extension and asking the patient to attempt to actively flex the DIP joint. In this injury, the pathognomonic finding is a straight, extended DIP joint with no active flexion. This injury is easily dismissed as a 'sprain' without performing this test, particularly in the absence of an obvious fracture. This injury highlights the importance of routinely examining each tendon to each finger of the hand (flexor pollicis longus, flexor digitorum superficialis and profundus); a single digit FDP avulsion is easily missed if the patient is asked to simply 'make a fist' (Supplementary Fig. 2, Supplementary digital content 2 <https://docs.google.com/leaf?id=0B6sz8zJWgtDVYTMyyZdmMjktZThhOS00MjI5LWJiMDYtMWIwNTIxODUxOWQz&hl=en&authkey=CJrf-fMJ>). With practice, formal complete tendon examination takes little time.

As with UCL injuries of the thumb, radiographs are useful but not diagnostic. There is most often a normal anteroposterior and lateral plain radiograph [48]. Sometimes, avulsion fractures are seen along the path of the FDP on the palmar aspect of the digit (Fig. 4): this is highly suggestive of FDP avulsion. A large fracture may be seen with only a little retraction of the FDP just proximal to the DIP joint, or a small fracture with the retraction to the level of the PIP joint [46].

Fig. 4



Typical flexor digitorum profundus avulsion fractures.

Irrespective of the radiographic findings, urgent referral to a hand surgeon is necessary as only early surgical reattachment of the FDP tendon to its insertion can restore active DIP joint motion. There is no role for conservative treatment. Significant tendon retraction is associated with collapse of the pulleys through which the tendons normally run, as well as loss of tendon blood supply, making primary repair impossible after 7–10 days [48]. This is particularly the case when the tendon retracts into the palm, usually when there is no visible fracture [46]. Considerably more complex surgical procedures, such as DIP joint fusion or tendon grafting, are then needed to improve function.

Conclusion

The clinical and radiological findings in the described injuries are characteristic. A healthy index of suspicion and knowledge of injury patterns will enable a clinician to make an accurate diagnosis. A misdiagnosed injury may have profound consequences for hand function. The absence of an obvious fracture should not prompt the clinician to dismiss a potentially serious injury as a sprain: this is a potential pitfall in FDP and volar plate avulsion. We hope that this study highlights the importance of obtaining a detailed history, a thorough examination and careful scrutiny of radiographs with knowledge of typical fracture patterns.

Our key points for the emergency physician are:

- (1) In thumb injuries, stress the RCL and UCL, comparing both injured and uninjured sides.
- (2) In PIP joint injuries, the clinician needs to see a true lateral radiograph to best assess injuries to the volar plate, looking carefully for subluxation. Suboptimal radiographs should be repeated.
- (3) FDP avulsion is a clinical diagnosis with a characteristic history: the key is to examine for a lack of active

motion at the DIP joint, looking at each digit in turn. All acute injuries need prompt surgery to restore function.

- (4) Bennett's fracture is inherently unstable and usually requires operative fixation.
- (5) Carefully consider the possibility of more than one injury.
- (6) A fracture cannot be excluded on a single radiographic view. At least two projections are essential on plain film imaging of hand injuries.
- (7) The frequent absence of fracture in UCL injury and FDP avulsion necessitates a thorough clinical examination for diagnosis.
- (8) The four injuries described will lead to loss of hand function if misdiagnosed.

Acknowledgements

The authors thank Angela Britcher for her help during the preparation of this manuscript.

There are no conflicts of interest.

References

- 1 Sahlin Y. Occurrence of fractures in a defined population: a 1-year study. *Injury* 1990; **21**:158–160.
- 2 Emmett JE, Breck LW. A review and analysis of 11 000 fractures seen in a private practice of orthopaedic surgery, 1937–1956. *J Bone Joint Surg Am* 1958; **40-A**:1169–1175.
- 3 O'Brien ET. The sprained finger that isn't. *Am Fam Physician* 1981; **23**:129–137.
- 4 Karcz A, Holbrook J, Burke MC, Doyle MJ, Erdos MS, Friedman M, et al. Massachusetts emergency medicine closed malpractice claims: 1988–1990. *Ann Emerg Med* 1993; **22**:553–559.
- 5 Magee DJ. Chapter 7: forearm, wrist and hand. *Orthopedic physical assessment*. 5th ed. St Louis, Missouri: Saunders; 2008. pp. 396–471.
- 6 Patel S, Potty A, Taylor EJ, Sorene ED. Collateral ligament injuries of the metacarpophalangeal joint of the thumb: a treatment algorithm. *Strategies Trauma Limb Reconstr* 2010; **5**:1–10.
- 7 Moberg E, Stener B. Injuries to the ligaments of the thumb and fingers; diagnosis, treatment and prognosis. *Acta Chir Scand* 1953; **106**:166–186.
- 8 Leversedge FJ. Anatomy and pathomechanics of the thumb. *Hand Clin* 2008; **24**:219–229.
- 9 Baskies MA, Lee SK. Evaluation and treatment of injuries of the ulnar collateral ligament of the thumb metacarpophalangeal joint. *Bull NYU Hosp Jt Dis* 2009; **67**:68–74.
- 10 Newland CC. Gamekeeper's thumb. *Orthop Clin North Am* 1992; **23**:41–48.
- 11 Johnson JW, Culp RW. Acute ulnar collateral ligament injury in the athlete. *Hand Clin* 2009; **25**:437–442.
- 12 Carr D, Johnson RJ, Pope MH. Upper extremity injuries in skiing. *Am J Sports Med* 1981; **9**:378–383.
- 13 Campbell CS. Gamekeeper's thumb. *J Bone Joint Surg Br* 1955; **37-B**:148–149.
- 14 Heyman P, Gelberman RH, Duncan K, Hipp JA. Injuries of the ulnar collateral ligament of the thumb metacarpophalangeal joint. Biomechanical and prospective clinical studies on the usefulness of valgus stress testing. *Clin Orthop Relat Res* 1993; **292**:165–171.
- 15 Cooper JG, Johnstone AJ, Hider P, Ardagh MW. Local anaesthetic infiltration increases the accuracy of assessment of ulnar collateral ligament injuries. *Emerg Med Australas* 2005; **17**:132–136.
- 16 Malik AK, Morris T, Chou D, Sorene E, Taylor E. Clinical testing of ulnar collateral ligament injuries of the thumb. *J Hand Surg Eur Vol* 2009; **34**:363–366.
- 17 Minami A, An KN, Cooney WP III, Linscheid RL, Chao EY. Ligamentous structures of the metacarpophalangeal joint: a quantitative anatomic study. *J Orthop Res* 1984; **1**:361–368.
- 18 Bowers WH, Hurst LC. Gamekeeper's thumb. Evaluation by arthrography and stress roentgenography. *J Bone Joint Surg Am* 1977; **59**:519–524.
- 19 Stener B. Skeletal injuries associated with rupture of the ulnar collateral ligament of the metacarpophalangeal joint of the thumb. A clinical and anatomical study. *Acta Chir Scand* 1963; **125**:583–586.
- 20 Perron AD, Brady WJ, Keats TE, Hersh RE. Orthopedic pitfalls in the emergency department: closed tendon injuries of the hand. *Am J Emerg Med* 2001; **19**:76–80.
- 21 Hintermann B, Holzach PJ, Schutz M, Matter P. Skier's thumb—the significance of bony injuries. *Am J Sports Med* 1993; **21**:800–804.
- 22 Husband JB, McPherson SA. Bony skier's thumb injuries. *Clin Orthop Relat Res* 1996; **327**:79–84.
- 23 Giele H, Martin J. The two-level ulnar collateral ligament injury of the metacarpophalangeal joint of the thumb. *J Hand Surg Br* 2003; **28**:92–93.
- 24 Thirkannad S, Wolff TW. The 'two fleck sign' for an occult Stener lesion. *J Hand Surg Eur Vol* 2008; **33**:208–211.
- 25 Smith RJ. Post-traumatic instability of the metacarpophalangeal joint of the thumb. *J Bone Joint Surg Am* 1977; **59**:14–21.
- 26 Glickel SZ, Barron OA, Catalano LW. Dislocations and ligament injuries in the digits. In: Green DP, Hotchkiss RN, Pederson WC, Wolfe SW, editor. *Green's operative hand surgery*. 5th ed. Philadelphia, Pa: Elsevier Inc; 2005.
- 27 Jones MH, England SJ, Muwanga CL, Hildreth T. The use of ultrasound in the diagnosis of injuries of the ulnar collateral ligament of the thumb. *J Hand Surg Br* 2000; **25**:29–32.
- 28 Edelman DM, Kardashian G, Lee SK. Radial collateral ligament injuries of the thumb. *J Hand Surg Am* 2008; **33**:760–770.
- 29 Bennett EH. Fractures of the metacarpal bones. *Dublin J Med Sci* 1882; **73**:72–75.
- 30 McGuigan FX, Culp RW. Surgical treatment of intra-articular fractures of the trapezium. *J Hand Surg Am* 2002; **27**:697–703.
- 31 Gedda KO. Studies on Bennett's fracture; anatomy, roentgenology, and therapy. *Acta Chir Scand Suppl* 1954; **193**:1–114.
- 32 Carlsen BT, Moran SL. Thumb trauma: Bennett fractures, Rolando fractures, and ulnar collateral ligament injuries. *J Hand Surg Am* 2009; **34**:945–952.
- 33 Timmenga EJ, Blokhuis TJ, Maas M, Raaijmakers EL. Long-term evaluation of Bennett's fracture. A comparison between open and closed reduction. *J Hand Surg Br* 1994; **19**:373–377.
- 34 Thurston AJ, Dempsey SM. Bennett's fracture: a medium to long-term review. *Aust N Z J Surg* 1993; **63**:120–123.
- 35 Stern PJ. Fractures of the metacarpals and phalanges. In: Green DP, editor. *Green's operative hand surgery*. 5th ed. Philadelphia: Elsevier, Churchill Livingstone; 2005.
- 36 Bailie DS, Benson LS, Marymont JV. Proximal interphalangeal joint injuries of the hand. Part I: anatomy and diagnosis. *Am J Orthop* 1996; **25**:474–477.
- 37 Bowers WH, Wolf JW Jr, Nehil JL, Bittinger S. The proximal interphalangeal joint volar plate. I. An anatomical and biomechanical study. *J Hand Surg Am* 1980; **5**:79–88.
- 38 Nance EP Jr, Kaye JJ, Milek MA. Volar plate fractures. *Radiology* 1979; **133**:61–64.
- 39 Kiefhaber TR, Stern PJ. Fracture dislocations of the proximal interphalangeal joint. *J Hand Surg Am* 1998; **23**:368–380.
- 40 Gaine WJ, Beardsmore J, Fahmy N. Early active mobilisation of volar plate avulsion fractures. *Injury* 1998; **29**:589–591.
- 41 Glickel SZ, Barron OA. Proximal interphalangeal joint fracture dislocations. *Hand Clin* 2000; **16**:333–344.
- 42 Light TR. Buttress pinning techniques. *Orthop Rev* 1981; **10**:49–55.
- 43 Sinnatamby CS. *Last's anatomy, regional and applied*. 10th ed. Edinburgh: Churchill Livingstone; 1999. Chapter 2.
- 44 Tuttle HG, Olvey SP, Stern PJ. Tendon avulsion injuries of the distal phalanx. *Clin Orthop Relat Res* 2006; **445**:157–168.
- 45 Lunn PG, Lamb DW. 'Rugby finger'—avulsion of profundus of ring finger. *J Hand Surg Br* 1984; **9**:69–71.
- 46 Leddy JP, Packer JW. Avulsion of the profundus tendon insertion in athletes. *J Hand Surg Am* 1977; **2**:66–69.
- 47 Bynum DK Jr, Gilbert JA. Avulsion of the flexor digitorum profundus: anatomic and biomechanical considerations. *J Hand Surg Am* 1988; **13**:222–227.
- 48 Leddy JP. Avulsions of the flexor digitorum profundus. *Hand Clin* 1985; **1**:77–83.